

Treatment of open apex teeth using two types of white mineral trioxide aggregate after initial dressing with calcium hydroxide in children

Abigail Moore, Mary Freda Howley, Anne C. O'Connell

Dublin Dental School & Hospital, Dublin 2, Ireland

Correspondence to: Abigail Moore, Burlington Dental Clinic, 16 Burlington Road, Dublin 4, Ireland
Tel.: +353 1 6684357
Fax: +353 1 6603919
e-mail: abigail.moore@dental.tcd.ie

Accepted 30 December, 2010

Abstract – Background: The clinical and radiographic success of two types of white mineral trioxide aggregate (MTA) as apical barriers in non-vital immature permanent incisors in children was investigated. **Materials and methods:** Following an initial dressing with calcium hydroxide, MTA apical barriers were placed in 22 non-vital traumatized, permanent incisors with open apices in 21 children (mean age 10 years). Teeth were alternately assigned to either white MTA ProRoot® or white MTA Angelus groups and treated by two operators. Clinical and radiographic reviews took place at baseline, 3 months and every 6 months thereafter. Two other calibrated, blinded examiners evaluated all radiographs. Examiner agreement was assessed using Kappa–Cohen tests. Results were analysed using Fisher's exact tests and repeated measures ANOVA. **Results:** The mean follow-up time was 23.4 months. There were no statistically significant differences in clinical or radiographic outcomes between the two groups. The overall clinical success and relative radiographic success rate was 95.5%. Statistically significant reduction in periapical pathosis was shown over time in both groups ($P < 0.05$). A significant relationship was identified between non-divergent apical anatomy and ideal positioning of the MTA plug in all teeth ($P = 0.04$). Interestingly, coronal discolouration was observed in 22.7% of teeth following white MTA placement. **Conclusions:** Apical barrier placement using both white MTA ProRoot® and white MTA Angelus after an initial calcium hydroxide dressing showed similar favourable clinical and radiographic outcomes.

Worldwide, 20–30% of 12-year-old children are experiencing dental trauma that may lead to damage of the developing dentition (1). When an injury damages Hertwig's root sheath (HERS) or causes pulp necrosis, root development may be arrested (2, 3). The resulting thinness of dentinal canal walls may predispose these teeth to fracture (4). Immature teeth have blunt ends and wide open apices making an optimal apical seal difficult to achieve (5, 6).

Apexification seeks to induce a calcified barrier in a root with an open apex (7). Various materials have been investigated to induce an apical barrier such as antiseptic or antibiotic pastes, tricalcium phosphate, camphorated monochlorophenol and calcium hydroxide (8–11). Apexification using calcium hydroxide as an intra-canal dressing has been the most widely used and clinically accepted for over 40 years. This technique is easy and clinically acceptable, with good success rates (12, 13). The treatment time frame is however unpredictable and often prolonged, risking loss of patient compliance (14). The extended presence of a temporary coronal restoration leaves teeth at risk of bacterial contamination, and there is an elevated risk of root fracture in teeth with long-term calcium hydroxide dressings (4, 15).

Apical closure in immature teeth may also be achieved by placement of an artificial apical barrier, allowing prompt obturation and restoration (7, 14). Mineral trioxide aggregate (MTA) has been introduced as the material of choice for this technique (16) with the limited body of clinical studies showing favourable results, comparable or superior to apexification with calcium hydroxide (17–21). MTA has many characteristics making it a suitable apical barrier material, including biocompatibility, sealability, low cytotoxicity and induction of a favourable tissue response (22–26). A white MTA ProRoot® (Dentsply Tulsa Dental, Tulsa, OK, USA) has gained popularity following reports of coronal discolouration with grey MTA, in an attempt to achieve better aesthetic results (20, 27). The composition of white MTA ProRoot® has been shown to differ from grey MTA ProRoot® only in the metal oxides content (28). Recently, another commercial brand of white and grey MTA Angelus (Angelus Dental Solutions, Londrina, Parana, Brazil) has entered the market. This material claims to offer a faster set time, improved handling characteristics and has been shown *in vitro* to be very similar in chemical composition and biocompatibility to MTA ProRoot® (29).

There is an abundance of *in vitro* evidence supporting the characteristics of MTA as a suitable apical barrier material (24, 25). Animal studies have provided much of the research investigating the favourable biological periapical response to MTA (30, 31). Other *in vivo* work in animals has explored factors affecting calcific bridge formation over MTA plugs (32, 33). There is, however, limited human research involving MTA for apexification (17–21, 34). There are no published reports on the use of white MTA Angelus. The use of white MTA ProRoot® is recorded in case reports (35, 36) but in only two clinical studies (19, 21). Otherwise, grey MTA has been used or the colour was not specified. There are no published reports comparing the white MTA products. There is therefore a gap in the literature of *in vivo* research involving white MTA ProRoot® and white MTA Angelus. Further evidence is required to determine whether white MTA may provide a better alternative to calcium hydroxide as the material of choice for apical closure in immature teeth.

The aim of this study was to investigate the clinical and radiographic success of apical barrier placement, using white MTA ProRoot® and white MTA Angelus in children with non-vital, immature permanent incisors.

Materials and methods

Ethical approval was attained from the Faculty of Health Sciences Research Committee of Trinity College Dublin, Ireland. The study population were identified from children attending the Trauma Clinic of Dublin

Dental School and Hospital between January 2007 and January 2008 who met the inclusion criteria (Table 1) (6). Teeth with non-vital pulps were identified using clinical and radiographic criteria and apical barrier placement was agreed as the appropriate treatment. Participants were alternately assigned to either Group 1 (ProRoot®) or Group 2 (Angelus). A comprehensive medical, dental and trauma history was recorded prior to a clinical examination and sensibility testing. Radiographic examination was performed using a size 2 film (Kodak; Carestream Health Inc., Rochester, NY, USA) and an anterior film holder (Dentsply Rinn Corp, Elgin, IL, USA) at exposure 70 Kv, 0.16 s. The cooperation of the patients was assessed at each visit using the Frankl Behaviour Rating Scale (37).

Two experienced operators carried out all treatments over three visits following a standardized protocol under 6× magnification (Optomic Microlux 150; Optomic, Madrid, Spain) and rubber dam isolation, with local anaesthesia where indicated (2% xylocaine 1:80000 adrenaline; Septodont, Kent, England). On the first visit, chemomechanical debridement was achieved using K File endodontic files (Dentsply, Maillefer, Switzerland) and 0.2% chlorhexidine gluconate irrigation (Corsodyl; GlaxoSmithKline, Dublin, Ireland) that has equal or superior antibacterial quality to sodium hypochlorite (38). The working length was determined both radiographically (Fig. 1a) and with an apex locator (Root ZX; J Morita MFG Corp., Kyoto, Japan). An open apex was diagnosed from radiographic appearance and confirmed clinically by lack of apical resistance detected using a size 80 K File at the working length. Calcium hydroxide (UltraCal XS; Ultradent Products Inc, South Jordan, UT, USA) was placed for at least 1 week.

At visit two, an initial increment of the allocated MTA material was delivered using a size 25 Messing Gun (S.A, Vevey, Switzerland) and tapped to the desired working length using premeasured paper points. A periapical radiograph was taken to confirm the initial MTA increment position, then 3–5 mm MTA was added and assessed radiographically (Fig. 1b). A paper point, moistened with sterile water, was placed in contact with the MTA plug. At visit three, the presence of a firm barrier of MTA cement was assessed using a K File prior to backfilling with thermoplasticized gutta percha (Obtura Corp., Fenton, MO, USA). A sealer was not used because of operator preference in this protocol.

Table 1. Summary of inclusion criteria for selected cases (6)

Inclusion criteria
<16 years old
Immature permanent incisor root
Non-vital tooth requiring endodontic therapy
Restorable tooth
No horizontal or vertical root fractures
No active root resorption (inflammatory or replacement)
≥½ root length developed
Fit and healthy patient (ASA/II) ¹
Informed consent achieved
Co-operative for treatment

¹American Society for Anesthesiologists Classification System.

Fig. 1. Radiographs showing stages of mineral trioxide aggregate (MTA) apical barrier technique in upper right central incisor: (a) Confirmation of working length using gutta percha. A large periapical radiolucency exists. [periapical index (PAI) score = 4, presence of a periapical radiolucency (PARL) recorded]; (b) 3–5 mm MTA plug in an ideal position; (c) 31 month follow-up post obturation and restoration showing complete resolution of periapical pathosis and a partial calcific apical bridge. (PAI score = 1, absence of a PARL recorded).

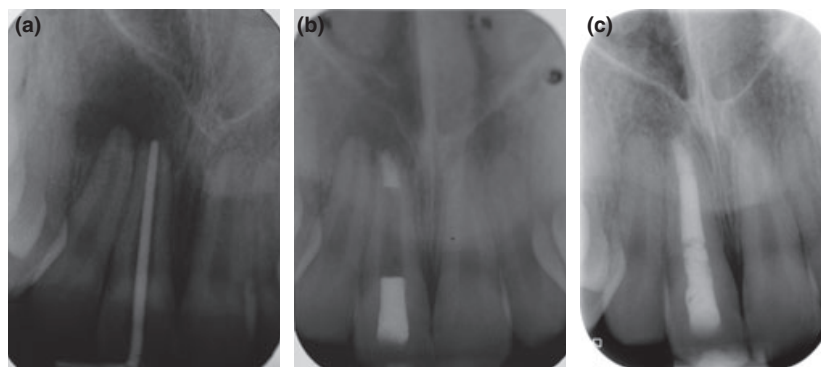


Table 2. Clinical tests and radiographic observations recorded

Clinical tests
Tenderness to percussion
percussion tone
Colour
Mobility
Swelling/sinus tract
Periodontal probing depth
Radiographic observations
Periapical index (39)
Periapical radiolucency (maximum horizontal diameter)
Apical anatomy (divergent/non-divergent)
Stage root development 1–5 (40)
Mineral trioxide aggregate plug position (ideal/non-ideal)
Calcific apical bridge (present/absent)

Coronally, a bright shade of composite resin (Esthet-X; Dentsply Caulk, Millford, DE, USA) or glass ionomer cement was placed, depending on the restorative treatment plan (Fig. 1c).

Clinical and radiographic variables, as described in Table 2, were recorded at baseline, 3 months and then every 6 months thereafter. A blinded examiner carried out the clinical examination and two blinded calibrated examiners evaluated all baseline and follow-up radiographs in a darkened room with light boxes and magnification (2.5 \times ; Lic Dental, Enkoping, Sweden). The criteria for clinical and radiographic success or failure are shown in Table 3. The absolute rate was used to describe teeth showing absolute success or failure, while the relative rate was the absolute rate plus relative outcomes, i.e. tendency towards healing/failure.

The PAI (periapical index) was used to assess and score chronic apical periodontitis from category 1–5 (39). The PAI aims to remove the subjective and un-reproducible nature of endodontic evaluation and reduces bias, allowing blinded evaluation of radiographs (39). The presence or absence of a periapical radiolu-

Table 3. Criteria of clinical and radiographic success

Clinical success
Absence of signs and symptoms of periapical disease
Absence of pain, tenderness to percussion, periodontal probing defects or presence of a swelling/sinus tract
Radiographic criteria
Absolute success
Normal periodontal ligament space, contour width and structure
PAI = 1
Absence PARL
Absolute failure
Increase in PAI
Increase or development of PARL
Relative success ¹
Decrease PAI >1
Decrease PARL but not complete resolution
Relative failure ²
Stable PAI >1
Stable PARL
PAI, periapical index; PARL, periapical radiolucency.
¹ Relative success rate = absolute success + relative success.
² Relative failure rate = absolute failure + relative failure.

ency (PARL) was noted, and the maximum horizontal diameter (for standardization of results) was measured where possible. A root development index was used to categorize the maturity of root development from stage 1 ($\frac{1}{4}$ length) to stage 5 (full length, $\frac{1}{2}$ open apex) (40). Apical anatomy was assessed as either divergent or non-divergent (parallel/convergent) in structure. The position of the MTA plug was scored as ideal or non-ideal (overfilled/underfilled) (Figs 1b and 2a,b). Radiographic appearance of a calcific apical bridge over the MTA plug was recorded as absent or present (partial/complete).

Statistical analysis was carried out using InStat[®] (GraphPad Software Inc., La Jolla, CA, USA) and JMP[®] (SAS Institute, Cary, NC, USA). Inter-examiner and intra-examiner calibration was analysed using the Kappa-Cohen test. Fisher Exact tests were used to compare groups of data and a Repeated Measures ANOVA assessed the PAI score change over time.

Results

Twenty-one patients were recruited with a mean age of 10 years (± 2 years). The gender balance was 72.7% men compared to 27.3% women. A total of 22 maxillary incisor teeth (20 central, two lateral) had been traumatized at an average age of 7.8 years (± 1.1 years). Injuries included uncomplicated crown fractures (40.9%), avulsion (22.7%), concussion (13.6%), complicated crown fractures (9.1%), extrusion (9.1%) and intrusion (9.1%). Dental anomalies (dens invaginatus and amelogenesis imperfecta) were concurrent in two cases.

All teeth were followed up for a minimum of 18 months postoperatively, with an average follow-up time of 23.4 months (± 4.8 months). All participants attended for reviews and none were lost to follow-up. The mean total treatment time (MTA placement to canal obturation) was 8.5 weeks (ranging from 2.3 to 22 weeks). All patients showed excellent behaviour, with nitrous oxide sedation required for one patient. Only one patient experienced discomfort following MTA plug placement. The handling properties of each material were examined. The only difference between both materials was that MTA Angelus had a creamier consistency when mixed, facilitating easier loading of the carrier gun. The white colour of both materials enhanced visualization within the root canal.

Radiographic variables

Baseline radiographic variables were examined to calculate inter-examiner and intra-examiner agreement. Kappa-Cohen test values were calculated, showing excellent agreement (> 0.77). When examining the radiographic variables, the results of both groups were compared as well as results of the whole sample 'the combined group'.

Root development and apical anatomy

The majority (77.3%) of teeth were stages 3 ($\frac{3}{4}$ length) and 4 (full length, open apex) root development (40). No teeth were at stage 1 development and 13.6% were at

Table 4. Contingency table showing the relationship of root development to apical anatomy

Root development	Apical anatomy					
	Divergent			Non-divergent		
	ProRoot	Angelus	Total	ProRoot	Angelus	Total
1-3	1	2	3	4	2	6
4-5	0	0	0	6	7	13
Total	3			19		

Table 5. Contingency table showing the relationship between root development and mineral trioxide aggregate (MTA) plug position

Root development	MTA plug position					
	Ideal			Non-ideal		
	ProRoot	Angelus	Total	ProRoot	Angelus	Total
1-3	2	2	4	3	2	5
4-5	6	4	10	0	3	3
Total	14			8		

Table 6. Contingency table showing the relationship of apical anatomy to mineral trioxide aggregate (MTA) plug position

Apical anatomy	MTA plug position					
	Ideal			Non-Ideal		
	ProRoot	Angelus	Total	ProRoot	Angelus	Total
Divergent	0	0	0	1	2	3
Non-divergent	8	6	14	2	3	5
Total	14			8		

stage 5. Parallel apical anatomy was recorded in 54.6% teeth and converging shape in 31.8%. Only 13.6% of teeth showed divergent apical anatomy compared to 86.4% non-divergent (parallel and converging). Distribution was similar between both groups. In the combined group, teeth with more mature root development (Stages 4-5) were frequently associated with non-divergent apices (Fisher's exact test $P = 0.055$) (Table 4).

MTA plug position

Ideal MTA plug position occurred in 63.6% while 27.3% were overfilled and 9.1% underfilled. An ideal plug was frequently observed with more mature teeth (stages 4 and 5) in the combined group, but this was not significant (Fisher's exact test $P = 0.187$) (Table 5). A Fisher's exact test identified a significant relationship ($P = 0.04$) between plug position and apical anatomy in the combined group, with ideal plugs frequently associated with non-divergent apices and divergent apices showing more non-ideal MTA placement (Table 6). All but one tooth with ideal MTA plug positioning experienced absolute success ($n = 13$). Figure 1b shows a radiograph of an ideal MTA plug, while Fig. 2a,b show non-ideal plug positions.

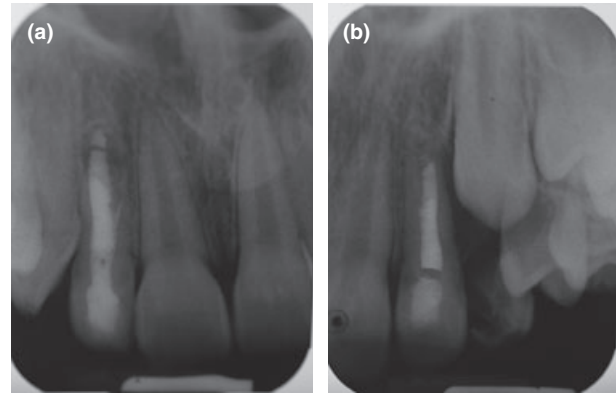


Fig. 2. Radiographs showing position of non-ideal mineral trioxide aggregate (MTA) plugs associated with divergent apical anatomy: (a) Upper right lateral incisor shows overfill with MTA; (b) Upper left lateral incisor shows underfill with MTA.

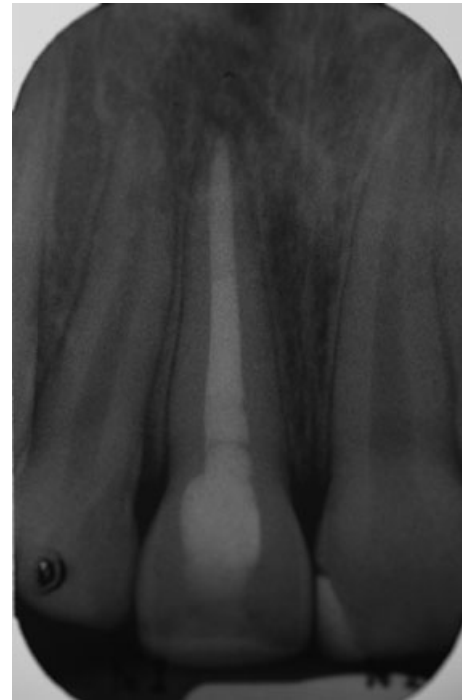


Fig. 3. Radiograph showing a complete calcific apical bridge in the upper right central incisor following placement of an mineral trioxide aggregate (MTA) barrier.

Calcific apical bridge

In the combined group, a calcific apical bridge was detectable over the MTA plug in 63.6% of teeth by 6 months and 36.4% did not form a calcific bridge during the study period. In 92.9% of cases, bridge formation was noted in association with non-divergent apices. Apical bridges formed in 71.4% teeth with an ideal MTA plug. The majority (76.5%) of teeth scoring absolute success showed bridge formation, and in 92.9% of cases, calcific bridging was seen in the context of absolute success. Figure 1c shows a partial calcific apical bridge and Fig. 3 shows a complete bridge, both in the context of absolute success.

Periapical index

A significant decrease in PAI scores was observed in both groups over time ($P = 0.03$, repeated measures ANOVA), and there was no difference in PAI outcome between the groups ($P = 1.000$). In the ProRoot® Group, the absolute success rate was 81.8% and the relative success rate was 90.9%, while in the Angelus Group, the absolute success rate was 100% after 18 months. The combined group absolute success rate was 90.9% with 95.5% showing relative success.

Periapical radiolucency

A PARL was present in 59.1% teeth at baseline, reducing to 9.1% at 18 months. There was no difference in PARL healing between ProRoot® and Angelus over time ($P = 1.00$). Analysis of the change in PARL status from baseline to 3 months ($P = 0.03$) and from 3 to 6 months ($P = 0.02$) demonstrated a significant reduction in PARL size. Using the PARL variable, results were identical to the PAI outcomes in both groups.

PAI and PARL

When both the PAI and PARL were considered in tandem, an overall absolute success rate of 90.9% and a relative success rate of 95.5% were calculated, with no difference between the groups. Figures 1a–c show a central incisor illustrating reduction in both PAI score and PARL dimension.

Clinical outcomes

There was only one clinical failure. Thus, the clinical success rate was 95.5% in the combined group over 18 months. Treatment was completed predictably in three visits, except in one instance where an MTA Angelus plug failed to set and was replaced.

Coronal discolouration occurred in five teeth (22.7%) following MTA placement. In three cases, the colour change was observed by the 3-month review, while in the two other cases, the discolouration was observed at the 18-month recall. White MTA Angelus was the apexification material in four of the discoloured teeth. Uncomplicated crown fractures were the initial trauma in three cases, while the others experienced avulsion and extrusive luxation. All the teeth that discoloured were stage 4–5 root development. Figure 4 shows an example of cervical coronal discolouration following white MTA placement.

Discussion

This study sought to compare two commercially available white MTA products and establish their effectiveness as apical barrier materials in immature permanent incisors.

The mean follow-up time of 23.4 (± 4.8) months is favourable, as healing of chronic apical periodontitis is reportedly evident in almost 90% of endodontic cases after 1 year (41). All but one tooth healed over the time

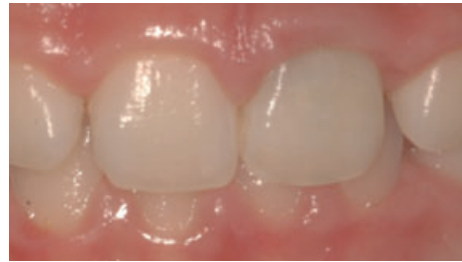

Fig. 4. Clinical photograph showing grey cervical coronal discolouration of an upper left central incisor following the placement of a white mineral trioxide aggregate (MTA) apical barrier.

frame of this study. Both types of MTA showed excellent clinical outcomes. The combined success rates of both materials (95.5%) compared favourably to other studies using both grey MTA and calcium hydroxide (13, 17, 20, 21). The only clinical failure was a very immature tooth presenting with a history of recurrent infection. Interestingly, a similar failure was reported by Pace et al. (42).

Excellent behaviour records indicate the procedure was acceptable to all children. Under ideal conditions, the total treatment time could be 1 week (17, 19); however, this varied in other studies from 1 to 10 weeks reported by Sarris et al. (20) and an average of 0.75 ± 0.49 months by Pradhan et al. (18). Prolonged treatment times (mean 8.5 weeks) in this study were primarily because of missed appointments. In one instance, an MTA Angelus plug failed to set requiring replacement. This tooth had a divergent apex, so perhaps, despite careful clinical drying of the canal, incorporation of chlorhexidine into the MTA occurred, which has been shown *in vitro* to inhibit the set (43). It is also possible that contact between the moist paper point and the MTA was not maintained. Despite delays, treatment time compared favourably to calcium hydroxide, where a recent prospective clinical trial reported an average of 12.19 months required for completing treatment (13).

No significant difference was shown using PAI outcome or PARL resolution between the materials. Results were therefore combined into a single group where necessary to allow meaningful comparison to the literature. We report a significant reduction in PAI and 84.6% healing of PARL at 18 months. Other similar studies report PARL healing of 65–100% (18, 19). The identical radiographic success rates of PAI and PARL indicate that the presence of baseline periapical pathosis does not negatively affect radiographic outcome. This is in agreement with the findings of Holden et al. 2008 and Nayar et al. 2009 (21, 34).

The 99.5% success rate for the combined PAI and PARL outcome in this research was shown to be superior to those of other studies reporting 76.5–85% (19–21). The success rate of apexification using calcium hydroxide has been reported to be between 74% and 100% (12, 13). El-Meligy et al. (17) reported an 87% success rate for calcium hydroxide apexification, compared to 100% in the MTA barrier group. The 90.9% absolute and 95.5% relative success of our results adds to

the evidence that white MTA is a predictable apical barrier material.

In this study, both groups showed a statistically significant relationship ($P = 0.04$) between ideal positioning of the MTA plug and non-divergent apical anatomy. It is more difficult to control MTA placement in blunderbuss apices. Extrusion occurs easily or under-fill may occur because of overcautious compaction (44, 45) (Figs 2a,b). A resorbable physical barrier may be placed to provide a surface to compact the MTA against, e.g. Collatape (Centerpulse Dental, Carlsband, CA, USA) and calcium sulphate (Class Implant, Rome, Italy) (46). This was not included in the standard protocol because of operator preference. However, owing to apparent strong association between non-ideal MTA plug placement and divergent teeth, shown in this study, perhaps barrier use would be prudent in such cases. Ideal MTA plugs were frequently associated with radiographic success, with only one ideal plug not experiencing absolute success. Conversely, Sarris et al. (20) and Erdem & Sepet (47) did not find an association between MTA plug position and treatment outcome.

Hard tissue apical bridges were noted in 64% of cases, with 92% in the context of absolute success; however, not all successful cases were associated with bridge detection. This suggests that the appearance of a radiographic barrier is not a prerequisite for clinical success but one of multiple factors to consider when assessing outcome. Additionally, some degree of hard tissue may be present but not detected radiographically. A similar observation was made by Simon et al. (19) who reported periapical bridges in only 26% cases, while 81% of cases were considered successful. The formation of an apical bridge occurred more readily in non-divergent apices, echoing studies using calcium hydroxide (48, 49). An ideal MTA plug was frequently seen with a calcific barrier, but lack of bridge formation was not associated with non-ideal plug position. Previously, lack of bridge formation has been reported with MTA plug extrusion (18, 33).

Continued root development was noted in this study ($n = 7$), subsequent to MTA placement, and had been explained by elements of HERS that survive trauma, inflammation and endodontic therapy (1). There have been some case reports documenting continued apical root development following calcium hydroxide apexification in non-vital immature teeth, but none following MTA barrier placement (50–52). Recently, cases of necrotic, immature teeth have undergone apexogenesis following dressing with a polyantibiotic paste (53, 54). Stem cells from apical papilla (SCAP) may survive infection and allow root maturation (55). The discovery of SCAP cells and the possibility of apexogenesis in necrotic immature cases are possibly leading to a paradigm shift in treatment approach and merit further investigation in the future (54).

Tooth discolouration is an important aesthetic concern in this age group. Discolouration has been reported following the use of grey MTA (20, 27). In the present study, 22.7% ($n = 5$) teeth of normal colour at baseline showed discolouration at follow-up. Most were in the Angelus Group ($n = 4$). This is the first report in the

literature of discolouration following white MTA placement as an apical barrier. The cause is unclear; the aesthetic MTA was placed apically, far from the cervical margin followed by a tooth coloured intra-coronal restoration, and all the discoloured teeth were more mature (stage 4–5) excluding immaturity as a contributing factor. There seemed to be no correlation with severity of traumatic injury, as three of the five teeth lost vitality following uncomplicated crown fractures. The use of chlorhexidine alone, which is substantive and does not possess tissue dissolving properties theoretically, may have contributed to discolouration. The leaching of MTA components through the dentine causing a cervical stain is another proposal. Colour change may be related to the chemical components or stability of these products. X-ray photoelectron spectroscopy or energy dispersive analysis could be carried out on the batches to assess composition.

Strict inclusion criteria limited participation in this study. Small patient numbers seem to be a limiting factor in similar studies (18, 20, 21). A larger sample size may allow statistical analysis identifying trends between the materials. It would also be interesting to stratify participants according to root development to examine how root maturity affects success and long-term predisposition to fracture. There is a need for larger, multi-centre clinical trials to allow conclusive statistical analysis and provide a more robust evidence base.

There was no difference in clinical or radiographic success rates between the two types of white MTA (ProRoot® or Angelus). Additionally, the presence of baseline periapical pathology did not seem to affect the outcome. A number of teeth experienced tooth discolouration following white MTA placement. This warrants need for further investigations to prevent this untoward aesthetic result. This is specially important because anterior teeth comprise the majority of cases requiring this treatment approach. Furthermore, a strong relationship was noted between non-divergent apices and the placement of ideal MTA plugs. The option of using resorbable barriers should therefore be explored in teeth with divergent apices.

In summary, this research has shown that white MTA used as an apical barrier material following an initial dressing with calcium hydroxide in immature permanent incisors produces excellent clinical results. Shortened treatment time, predictable apical stop and acceptability make the use of white MTA an attractive treatment option for non-vital immature teeth in children.

References

1. Andreasen JO, Andreasen FM, Andersson L. Textbook and color atlas of traumatic injuries to the teeth, 4th edn. Oxford: Blackwell Munksgaard; 2007.
2. Barnett F. The role of endodontics in the treatment of luxated permanent teeth. *Dent Traumatol* 2002;18:47–56.
3. Avery JK, Chiego DJ. Essentials of oral histology and embryology: a clinical approach, 3rd edn. St. Louis: Mosby; 2006.
4. Andreasen JO, Farik B, Munksgaard EC. Long-term calcium hydroxide as a root canal dressing may increase risk of root fracture. *Dent Traumatol* 2002;18:134–7.

5. Rafter M. Apexification: a review. *Dent Traumatol* 2005;21:1–8.
6. Walton RE, Torabinejad M. Principles and practice of endodontics, 3rd edn. USA: Saunders; 2002. 334–6 pp.
7. American Association of Endodontists. Glossary of endodontic terms, 7th edn. Chicago: American Association of Endodontists; 2003.
8. Cooke C, Rowbotham TC. Root canal therapy in non-vital teeth with open apices. *Br Dent J* 1960;108:147–50.
9. Ball JS. Apical root formation in non-vital immature permanent incisor. Report of a case. *Br Dent J* 1964;116:166–7.
10. Kaiser HJ. Management of wide open apex canals with calcium hydroxide. Presented at the 21st annual Meeting of the American Association of Endodontists, Washington DC April 17th 1964.
11. Frank AL. Therapy for the divergent pulpless tooth by continued apical formation. *J Am Dent Assoc* 1966;72:87–93.
12. Sheehy EC, Roberts GJ. Use of calcium hydroxide for apical barrier formation and healing in non-vital immature permanent teeth: a review. *Br Dent J* 1997;183:241–6.
13. Dominguez Reyes A, Muñoz Muñoz L, Aznar Martín T. Study of calcium hydroxide apexification in 26 young permanent incisors. *Dent Traumatol* 2005;21:141–5.
14. Witherspoon DE, Ham K. One-visit apexification: technique for inducing root-end barrier formation in apical closures. *Pract Proced Aesthet Dent* 2001;13:455–60.
15. Andreassen JO, Munksgaard EC, Bakland LK. Comparison of fracture resistance in root canals of immature sheep teeth after filling with calcium hydroxide or MTA. *Dent Traumatol* 2006;22:154–6.
16. Torabinejad M, Hong CU, McDonald F, Pitt Ford TR. Physical and chemical properties of a new root-end filling material. *J Endod* 1995;21:349–53.
17. El-Meligy OA, Avery DR. Comparison of apexification with mineral trioxide aggregate and calcium hydroxide. *Pediatr Dent* 2006;28:248–53.
18. Pradhan DP, Chawla HS, Gauba K, Goyal A. Comparative evaluation of endodontic management of teeth with unformed apices with mineral trioxide aggregate and calcium hydroxide. *J Dent Child (Chic)* 2006;73:79–85.
19. Simon S, Rilliard F, Berdal A, Machtou P. The use of mineral trioxide aggregate in one-visit apexification treatment: a prospective study. *Int Endod J* 2007;40:186–97.
20. Sarris S, Tahmassebi JF, Duggal MS, Cross IA. A clinical evaluation of mineral trioxide aggregate for root-end closure of non-vital immature permanent incisors in children—a pilot study. *Dent Traumatol* 2008;24:79–85.
21. Holden DT, Schwartz SA, Kirkpatrick TC, Schindler WG. Clinical outcomes of artificial root-end barriers with mineral trioxide aggregate in teeth with immature apices. *J Endod* 2008;34:812–7.
22. Koh ET, McDonald F, Pitt Ford TR, Torabinejad M. Cellular response to mineral trioxide aggregate. *J Endod* 1998;24:543–7.
23. De Deus G, Ximenes R, Gurgel-Filho ED, Plotkowski MC, Coutinho-Filho T. Cytotoxicity of MTA and Portland cement on human ECV 304 endothelial cells. *Int Endod J* 2005;38:604–9.
24. Parirokh M, Torabinejad M. Mineral trioxide aggregate: a comprehensive literature review – part I: chemical, physical, and antibacterial properties. *J Endod* 2010;36:16–27.
25. Torabinejad M, Parirokh M. Mineral trioxide aggregate: a comprehensive literature review – part II: leakage and biocompatibility investigations. *J Endod* 2010;36:190–202.
26. Economides N, Pantelidou O, Kokkas A, Tziafas D. Short-term periradicular tissue response to mineral trioxide aggregate (MTA) as root-end filling material. *Int Endod J* 2003;36:44–8.
27. Parirokh M, Torabinejad M. Mineral trioxide aggregate: a comprehensive literature review – part III: clinical applications, drawbacks, and mechanism of action. *J Endod* 2010;36:400–13.
28. Asgary S, Parirokh M, Eghbal MJ, Brink F. Chemical differences between white and gray mineral trioxide aggregate. *J Endod* 2005;31:101–3.
29. Song JS, Mante FK, Romanow WJ, Kim S. Chemical analysis of powder and set forms of Portland cement, gray ProRoot MTA, white ProRoot MTA, and gray MTA-Angelus. *Oral Surg Oral Med Oral Pathol Oral Radiol Endod* 2006;102:809–15.
30. Baek SH, Plenck H Jr, Kim S. Periapical tissue responses and cementum regeneration with amalgam, SuperEBA, and MTA as root-end filling materials. *J Endod* 2005;31:444–9.
31. Ham KA, Witherspoon DE, Gutmann JL, Ravindranath S, Gait TC, Opperman LA. Preliminary evaluation of BMP-2 expression and histological characteristics during apexification with calcium hydroxide and mineral trioxide aggregate. *J Endod* 2005;31:275–9.
32. Felipe WT, Felipe MC, Rocha MJ. The effect of mineral trioxide aggregate on the apexification and periapical healing of teeth with incomplete root formation. *Int Endod J* 2006;39:2–9.
33. Shabahang S, Torabinejad M, Boyne PP, Abedi H, McMillan P. A comparative study of root-end induction using osteogenic protein-1, calcium hydroxide, and mineral trioxide aggregate in dogs. *J Endod* 1999;25:1–5.
34. Nayar S, Bishop K, Alani A. A report on the clinical and radiographic outcomes of 38 cases of apexification with mineral trioxide aggregate. *Eur J Prosthodont Restor Dent* 2009;17:150–6.
35. Karp J, Bryk J, Menke E, McTigue D. The complete endodontic obturation of an avulsed immature permanent incisor with mineral trioxide aggregate: a case report. *Pediatr Dent* 2006;28:273–8.
36. D'Arcangelo C, D'Amario M. Use of MTA for orthograde obturation of nonvital teeth with open apices: report of two cases. *Oral Surg Oral Med Oral Pathol Oral Radiol Endod* 2007;104:e98–101.
37. Frankl SN, Shiere F, Fogels H. Should the parent remain with the child in the dental operator? *J Dent Child* 1962;29:150–63.
38. Vahdaty A, Pitt Ford TR, Wilson RF. Efficacy of chlorhexidine in disinfecting dentinal tubules *in vitro*. *Endod Dent Traumatol* 1993;9:243–8.
39. Orstavik D, Kerekes K, Eriksen HM. The periapical index: a scoring system for radiographic assessment of apical periodontitis. *Endod Dent Traumatol* 1986;2:20–34.
40. Andreassen FM, Pedersen BV. Prognosis of luxated permanent teeth – the development of pulp necrosis. *Endod Dent Traumatol* 1985;1:207–20.
41. Orstavik D. Time-course and risk analyses of the development and healing of chronic apical periodontitis in man. *Int Endod J* 1996;29:150–5.
42. Pace R, Giuliani V, Pagavino G. Mineral trioxide aggregate in the treatment of external invasive resorption: a case report. *Int Endod J* 2008;41:258–66.
43. Kogan P, He J, Glickman GN, Watanabe I. The effects of various additives on setting properties of MTA. *J Endod* 2006;32:569–72.
44. Hachmeister DR, Schindler WG, Walker WA III, Thomas DD. The sealing ability and retention characteristics of mineral trioxide aggregate in a model of apexification. *J Endod* 2002;28:386–90.
45. Martin RL, Monticelli F, Brackett WW, Loushine RJ, Rockman RA, Ferrari M et al. Sealing properties of mineral trioxide aggregate orthograde apical plugs and root fillings in an *in vitro* apexification model. *J Endod* 2007;33:272–5.
46. Kratchman SI. Obturation of the root canal system. *Dent Clin North Am* 2004;48:203–15.
47. Erdem AP, Sepet E. Mineral trioxide aggregate for obturation of maxillary central incisors with necrotic pulp and open apices. *Dent Traumatol* 2008;24:e38–41.
48. Yates JA. Barrier formation time in non-vital teeth with open apices. *Int Endod J* 1988;21:313–9.

49. Finucane D, Kinirons MJ. Non-vital immature permanent incisors: factors that may influence treatment outcome. *Endod Dent Traumatol* 1999;15:273–7.
50. Yang SF, Yang ZP, Chang KW. Continuing root formation following apexification treatment. *Endod Dent Traumatol* 1990;6:232–5.
51. Gupta S, Sharma A, Dang N. Apical bridging in association with regular root formation following single-visit apexification: a case report. *Quintessence Int* 1999;30:560–2.
52. Selden HS. Apexification: an interesting case. *J Endod* 2002;28:44–5.
53. Thibodeau B, Trope M. Pulp revascularization of a necrotic infected immature permanent tooth: case report and review of the literature. *Pediatr Dent* 2007;29:47–50.
54. Huang GT. A paradigm shift in endodontic management of immature teeth: conservation of stem cells for regeneration. *J Dent* 2008;36:379–86.
55. Sonoyama W, Liu Y, Yamaza T, Tuan RS, Wang S, Shi S et al. Characterization of the apical papilla and its residing stem cells from human immature permanent teeth: a pilot study. *J Endod* 2008;34:166–71.