



# Orthodontic uprighting of a horizontally impacted third molar and protraction of mandibular second and third molars into the missing first molar space for a patient with posterior crossbites

Un-Bong Baik,<sup>a</sup> Myung-Rae Kim,<sup>b</sup> Kyu-Ho Yoon,<sup>c</sup> Yoon-Ah Kook,<sup>d</sup> and Jae Hyun Park<sup>e</sup>  
Seoul, Korea, and Mesa, Ariz

A 22-year-old woman came with a unilateral missing mandibular first molar and buccal crossbite. The open space was closed by protraction of the mandibular left second molar and uprighting and protraction of the horizontally impacted third molar using temporary skeletal anchorage devices, and her buccal crossbite was corrected with modified palatal and lingual appliances. The total active treatment time was 36 months. Posttreatment records after 9 months showed excellent results with a stable occlusion. (*Am J Orthod Dentofacial Orthop* 2017;151:572-82)

The development of temporary skeletal anchorage devices (TSADs) has opened a new paradigm in modern orthodontics, offering treatment options for many difficult conditions that were untreatable with conventional methods. Absolute anchorage can be achieved with TSADs because the anchorage device is fixed in bone, eliminating anchorage loss that caused dental shifting or tilting, side-effects commonly seen with conventional intraoral anchorage appliances.<sup>1</sup>

Edentulous spaces caused by missing mandibular first molars are a common problem for clinicians. Various methods have been used to replace or remove

this condition: dental implants, dental bridges, and space closure with orthodontics. TSADs allow maximum anchorage for molar protraction to close these spaces.<sup>2,3</sup>

Likewise, a posterior crossbite is a common malocclusion in deciduous and mixed dentitions.<sup>4</sup> It has been claimed that stimuli through the teeth and musculature are what maintain alveolar bone architecture and shape.<sup>5</sup> Changes in the stimuli acting on the bone cause bone remodeling. If a posterior crossbite is left untreated, it can lead to skeletal deformation, so it is imperative that tooth position and musculature be corrected as soon as possible to prevent complications.<sup>6</sup>

The primary feature of posterior crossbite is at least 1 tooth in the maxillary arch ectopically positioned buccally or lingually with respect to the corresponding mandibular tooth or teeth.<sup>7</sup> Posterior crossbite can be bilateral or unilateral. It also has been reported that in children with unilateral posterior crossbite, the activity of the temporal and masseter muscles can be disturbed, and that adolescent patients with posterior crossbite have an increased risk of developing temporomandibular disorders.<sup>8</sup> Better prognosis and simple correction of posterior crossbites are possible when patients are in the deciduous and mixed dentitions; therefore, a posterior crossbites should be corrected early to eliminate future functional and skeletal problems.<sup>9</sup> If these patients are treated as adults, we predict more side effects and prolonged treatment times.<sup>10</sup>

<sup>a</sup>Private practice, Seoul, Korea.

<sup>b</sup>Department of Oral and Maxillofacial Surgery, Mokdong Hospital, Ewha Womans University, Seoul, Korea.

<sup>c</sup>Department of Oral and Maxillofacial Surgery, Sanggye Paik Hospital, Inje University, Seoul, Korea.

<sup>d</sup>Department of Orthodontics, Seoul St. Mary's Hospital, College of Medicine, Catholic University of Korea, Seoul, Korea.

<sup>e</sup>Postgraduate Orthodontic Program, Arizona School of Dentistry & Oral Health, A. T. Still University, Mesa, Ariz; Graduate School of Dentistry, Kyung Hee University, Seoul, Korea

All authors have completed and submitted the ICMJE Form for Disclosure of Potential Conflicts of Interest, and none were reported.

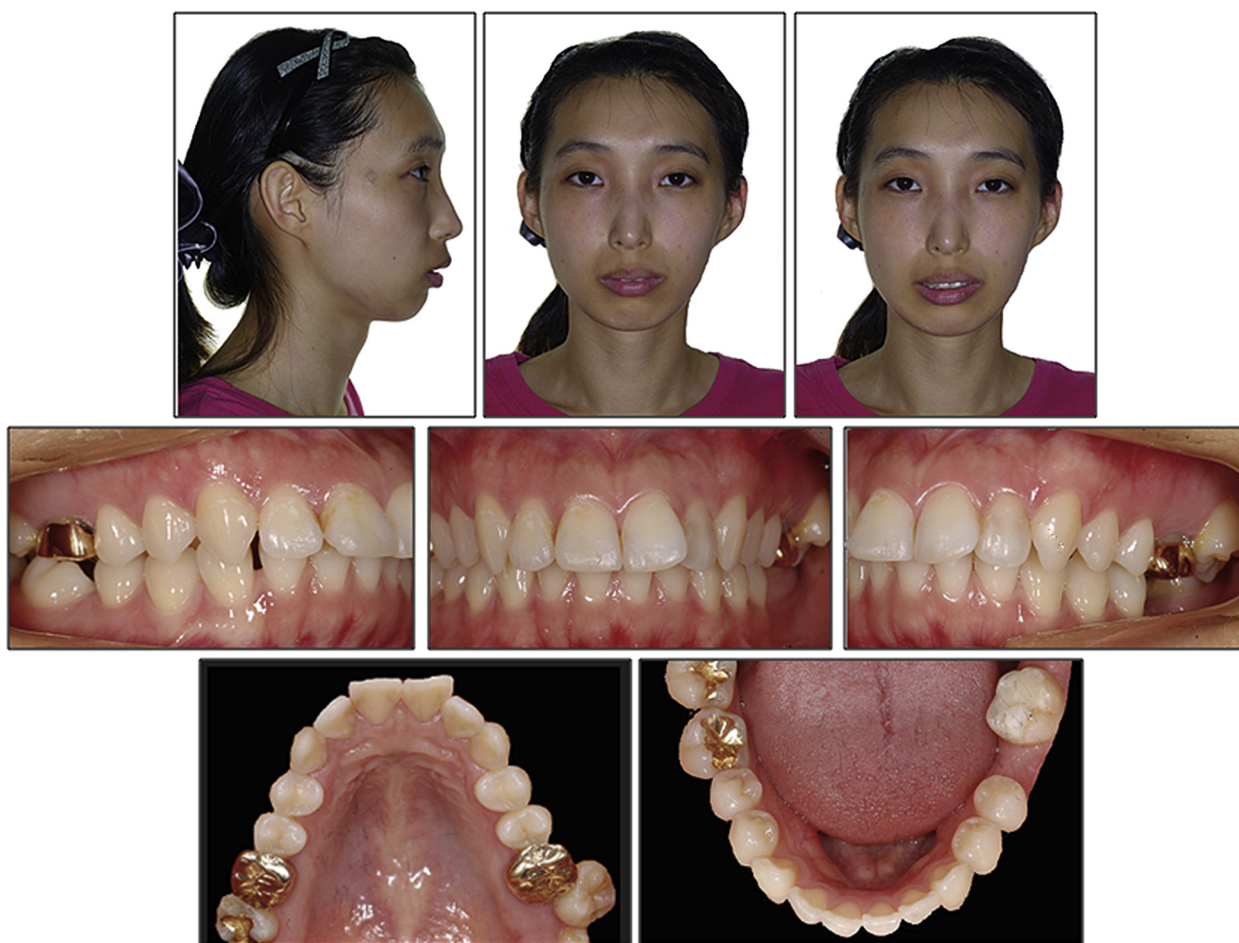Address correspondence to: Jae Hyun Park, Postgraduate Orthodontic Program, Arizona School of Dentistry & Oral Health, A. T. Still University, 5835 E Still Cir, Mesa, AZ 85206; e-mail, [JPark@atsu.edu](mailto:JPark@atsu.edu).

Submitted, November 2015; revised and accepted, January 2016.

0889-5406/\$36.00

© 2016 by the American Association of Orthodontists. All rights reserved.

<http://dx.doi.org/10.1016/j.ajodo.2016.01.019>



**Fig 1.** Pretreatment facial and intraoral photographs.

In this case report, we present a woman with posterior crossbites and a missing mandibular left first molar. Her buccal crossbite was corrected successfully with modified palatal and lingual appliances, and the lingual crossbite was improved with wire expansion. Her missing mandibular left first molar space was closed by protraction of the left second molar and uprighting and protraction of the third molar using TSADs and a mandibular lingual holding arch with an extension arm. See [Supplemental Materials](#) for a short video presentation about this study.

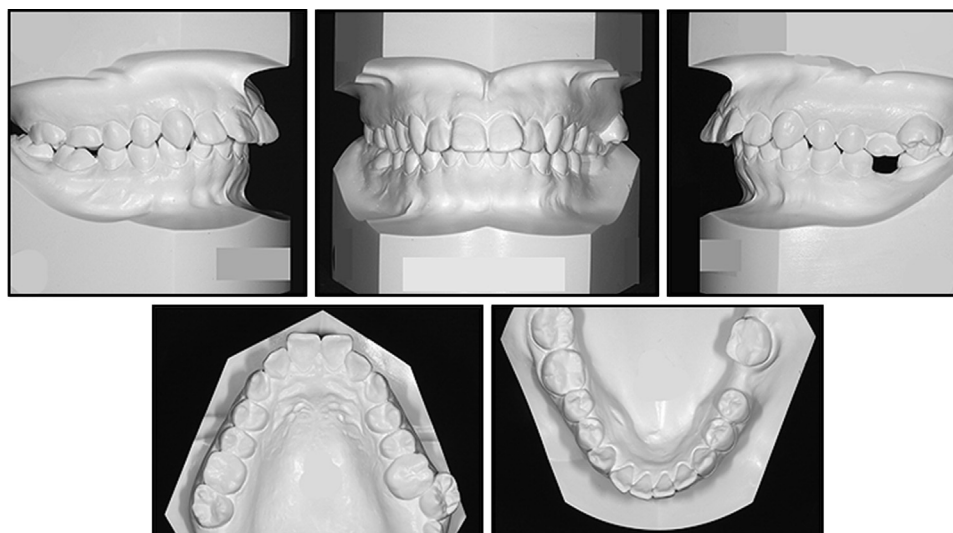#### **DIAGNOSIS AND ETIOLOGY**

A 22-year-old woman was referred to a private office for an evaluation of orthodontic treatment. Her chief complaint was protrusion of her maxillary anterior teeth. She had a dolichofacial pattern and a Class II appearance. A hyperactive mentalis muscle with lip strain was seen when she attempted to close her lips. She also

had decreased lower anterior facial height. There was no significant facial asymmetry.

Intraorally, she had proclined maxillary incisors with overjet of 8.5 mm and overbite of 70%. She showed an end-on Class II molar relationship on her right side, but the left-side molar occlusion was not classified because of her missing mandibular left first molar. She had moderate crowding in her maxillary arch and a deep curve of Spee in her mandibular arch. In addition, she had a slight lingual crossbite on her maxillary right first molar and a buccal crossbite on the maxillary left second molar. The occlusal anatomy and contour of the maxillary first molar crowns were poor. When her mandible was guided into centric relation, a functional shift was detected because of her posterior crossbites. Compared with her facial midline, her maxillary dental midline was coincident, but her mandibular dental midline was deviated 1.5 mm to the right ([Figs 1 and 2](#)).

A panoramic radiograph showed slightly different right and left condylar heads, but during the



**Fig 2.** Pretreatment dental casts.

temporomandibular joint evaluation, the patient did not report any muscle or joint pain or other symptoms typically associated with temporomandibular disease. She was missing her right third molars. She had a maxillary left third molar (microdontia) and a horizontally impacted mandibular left third molar. The root apices of the mandibular third molar were close to the inferior alveolar nerve. The mandibular left second premolar had a dilacerated root, and the mandibular right molars showed mesial tilting. Her maxillary first molars had been restored with crowns after endodontic treatment.

The lateral cephalometric analysis indicated a skeletal Class II pattern (ANB,  $5.5^\circ$ ) with a hyperdivergent growth pattern (SN-MP,  $40.0^\circ$ ). The maxillary and mandibular incisors were proclined (U1-SN,  $112.0^\circ$ ; IMPA,  $98.0^\circ$ ) (Fig 3; Table).

#### TREATMENT OBJECTIVES AND PLAN

The following treatment objectives were established: (1) relieve crowding in the maxillary arch and close the space in the mandibular arch, (2) correct the posterior crossbites, (3) establish Class I canine and Class I (or Class II) molar relationships, (4) obtain normal overjet and overbite, (5) level the curve of Spee, (6) improve the deviation when she opened her mouth and correct the dental midline, (7) obtain a stable occlusal relationship, and (8) improve facial and dental esthetics by establishing an esthetic smile.

With TSADs, distal movement of maxillary anterior teeth or mesial movement of mandibular posterior teeth would be possible without anchorage loss.<sup>2,3,11-13</sup> Because the patient wanted to retract her upper lip as much as possible, the plan was to extract her maxillary

first premolars. To camouflage the skeletal Class II pattern without a dental implant restoration (as per the patient's request), her mandibular second premolars were not extracted even though her mandibular incisors were proclined. The treatment plan was to protract her mandibular left second molar as a substitute for the first molar and protract her impacted third molar to replace the second molar after surgical exposure and uprighting. To correct the lingual crossbite on the maxillary right first molar, wire expansion was planned. To correct the buccal crossbite on the maxillary left second molar, modified palatal and lingual appliances were planned to be used.

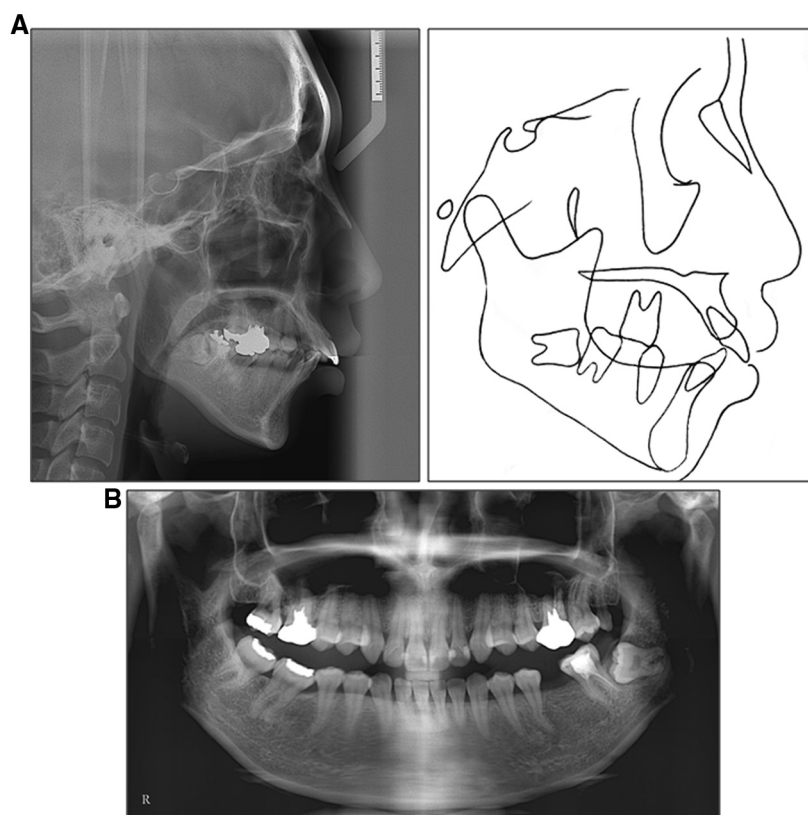
#### TREATMENT ALTERNATIVES

With no possibility of growth modification, correction of the Class II malocclusion could be accomplished by nonextraction total-arch distalization of the maxillary arch using TSADs after extraction of the maxillary left third molar or extraction of the maxillary first premolars and the mandibular second premolars with a dental implant restoration.

Because of her skeletal discrepancies that resulted from an unfavorable Class II skeletal growth pattern, a 2-jaw surgical procedure was also discussed. Upon completion of the orthodontic treatment, genioplasty would be another option to improve her profile, but the patient declined all surgical options.

#### TREATMENT PROGRESS

Before orthodontic treatment, the patient was referred to a general dentist to verify that there were no cavities and for extraction of the maxillary first



**Fig 3.** Pretreatment radiographs: **A**, lateral cephalogram; **B**, panoramic radiograph.

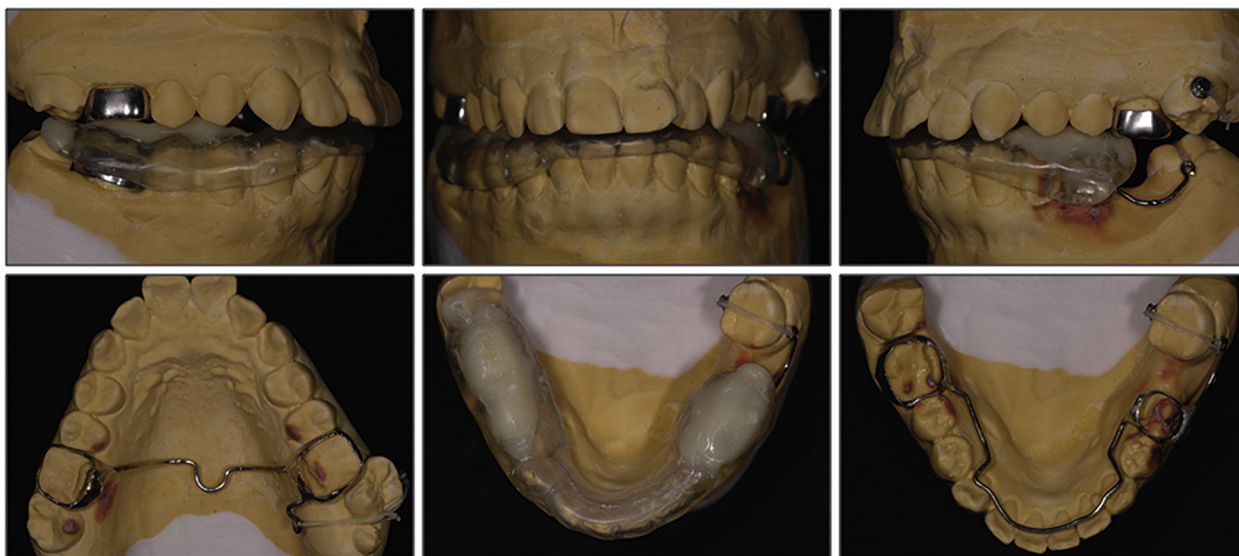**Table.** Cephalometric measurements

Measurement	Norm	Pretreatment	Posttreatment	9-month retention
SNA (°)	82.0	77.5	77.0	77.5
SNB (°)	80.0	72.0	71.0	71.5
ANB (°)	2.0	5.5	5.0	5.0
Wits (mm)	-1.0	3.5	-1.5	-1.0
SN-MP (°)	32.0	40.0	41.0	41.0
FH-MP (°)	24.0	34.0	35.0	35.5
LFH (ANS-Me/N-Me) (%)	55.0	51.3	55.0	55.5
U1-SN (°)	104.0	112.0	94.0	93.5
IMPA (°)	90.0	98.0	100.0	100.0
U1/L1 (°)	131.0	107.0	124.0	124.5
Upper lip (mm)	-4.0	3.0	0.0	0.0
Lower lip (mm)	-2.0	4.0	1.5	1.5

premolars and left third molar. After examining her dentition, the general dentist recommended that the maxillary left second premolar be extracted instead of the first premolar because of dental caries. To correct her maxillary left second molar buccal crossbite, a modified transpalatal arch with a soldered hook was used on the maxillary arch, and a modified lingual holding arch with a soldered hook was used on the mandibular arch. Buttons were bonded on the buccal and lingual

surfaces of the target teeth, and elastomeric chains were engaged occlusally. To allow clearance during crossbite correction, a removable appliance was also delivered (Fig 4).

The buccal crossbite was corrected within 3 months, and then full fixed 0.018-in metal twin brackets (Dentsply GAC, York, Pa) were placed and bonded in both arches except for the maxillary incisors per the patient's request for esthetic reasons. After leveling and



**Fig 4.** Modified transpalatal arch with soldered hook was used on the maxillary arch, and modified lingual holding arch with a soldered hook was used on the mandibular arch to correct the buccal cross-bite on the maxillary left second molar.

alignment, 2 TSADs (6.0 mm length, 1.5 mm diameter; Orlus, Seoul, Korea) were placed on the mesial area of the maxillary first molars to provide maximum anchorage. In the mandible, 1 miniscrew (6.0 mm length, 1.5 mm diameter; Orlus) was installed between the mandibular right canine and first premolar to maintain the corrected dental midline during protraction of the left molars and to help with the uprighting of the mesially tilted right molars. To protract her mandibular left molars, 1 miniscrew (6.0 mm length, 1.5 mm diameter; Orlus) was placed at the distal aspect of the left second premolar. The maxillary extraction spaces were closed with elastomeric chains from the canines to the TSADs. After a few months of space closure, the patient agreed to the bonding of her maxillary incisors, and space closing was continued. Because of the long span between the mandibular left second premolar and the second molar, the extraction space was closed with light elastomeric chains from the soldered hook between the left lateral incisor and the canine to the second molar using 0.016 × 0.025-in stainless steel wire. Additionally, a TSAD was used to protract the second molar (Fig 5).

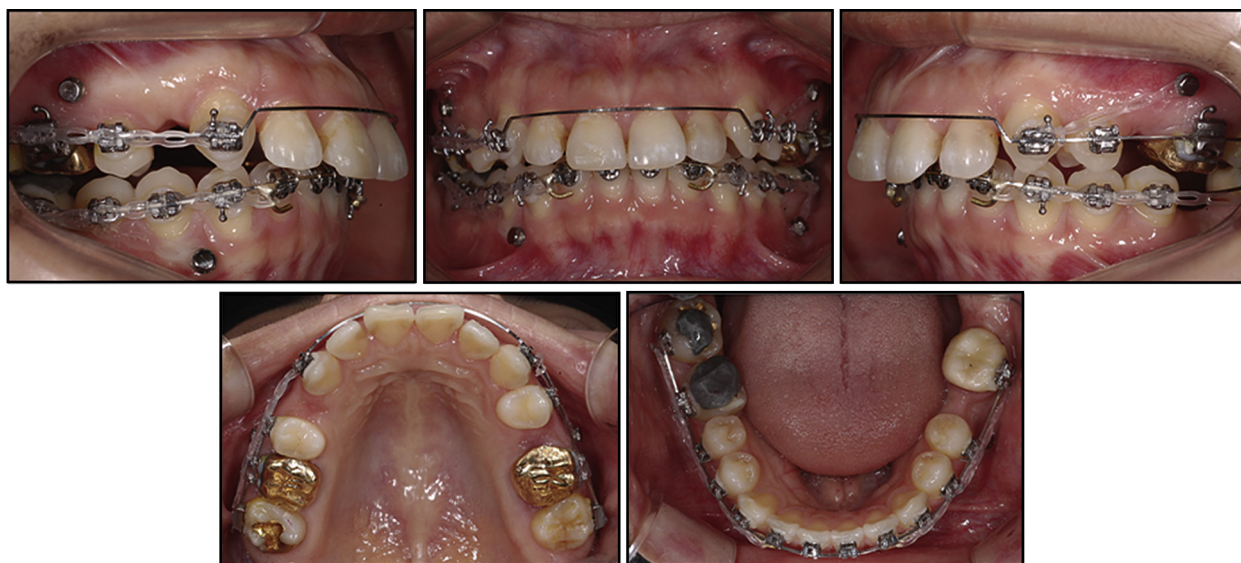After the left second molar was protracted and room was made to upright the impacted third molar, a mandibular lingual holding arch with an extension arm was delivered after surgical exposure of the third molar with a button. After the full crown portion of the third molar had successfully emerged, the tooth was bonded with a molar tube (Fig 6).

During the finishing stage, final detailing of the occlusion was accomplished with 0.016 × 0.022-in steel archwires. Fixed retainers were attached on the maxillary and mandibular anterior teeth. Wraparound removable retainers were also delivered to secure the stability of both arches. Total treatment time for this patient was 36 months.

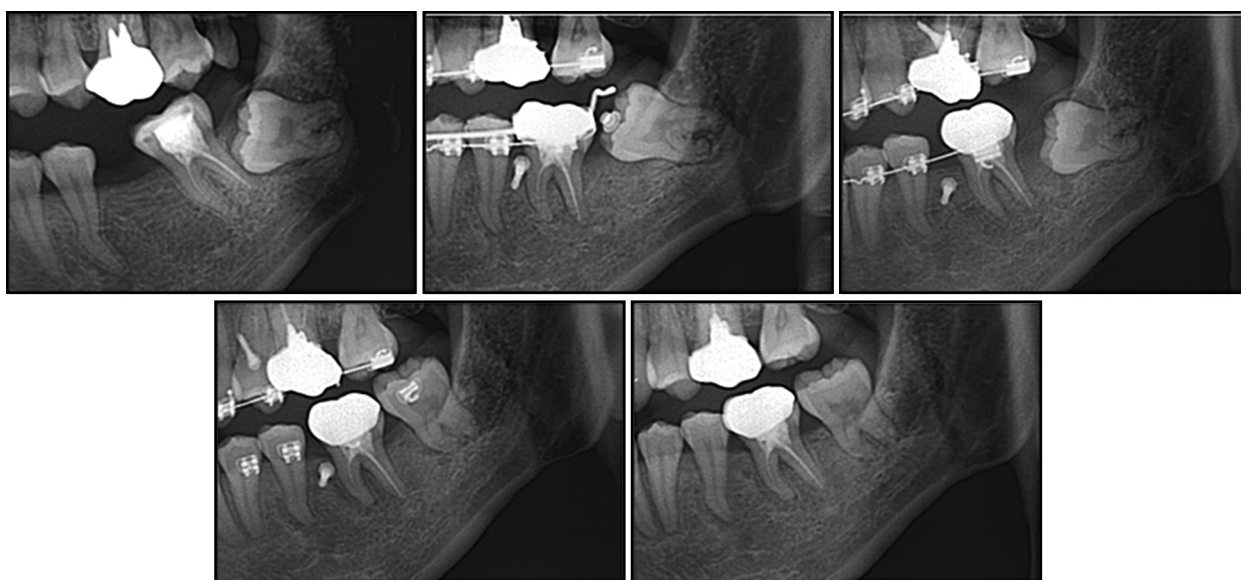
#### TREATMENT RESULTS

Posttreatment records showed that the treatment objectives were achieved. Facial photographs showed improved lip closure and reduced lip strain. The buccal crossbite on the patient's maxillary left second molar was corrected. Because of the occlusal anatomy and contour of the maxillary right first molar crown, the maxillary right first molar showed an edge-to-edge bite after treatment. The missing molar space was closed successfully (Figs 7 and 8).

The crowding in the patient's maxillary arch was relieved, acceptable overbite and overjet were achieved, and her dental midlines were improved. A Class II molar relationship was established, and the canine relationship was improved. At the finishing stage, enameloplasty was recommended because of her pointed maxillary right canine tip, but she declined the procedure. She also had composite buildups on the distal aspect of the maxillary left lateral incisor and the mesial aspect of the canine for minor space closing due to an anterior Bolton discrepancy, but she declined the composite



**Fig 5.** Progress photographs showing space closing of the maxillary arch and protraction of the mandibular left second molar using TSADs.



**Fig 6.** Progress radiographic images showing protraction of the mandibular second molars, and up-righting and protraction of the impacted third molar using a modified mandibular lingual holding arch with a soldered hook.

buildup on the distal aspect of the maxillary left canine (Figs 7 and 8).

The posttreatment panoramic radiograph showed proper space closure (except between the maxillary right canine and second premolar), acceptable root parallelism, and no significant signs of bone or root resorption. Posttreatment lateral cephalometric analysis and

superimposition showed no significant skeletal changes (ANB, 5.0°; SN-MP, 41.0°). The maxillary incisor proclination was improved with retroclination (U1-SN, 94.0°), and the mandibular incisor proclination was slightly increased (IMPA, 100°) compared with pretreatment (IMPA, 98.0°) to camouflage the skeletal Class II discrepancy (Figs 9 and 10; Table). The patient’s facial profile,

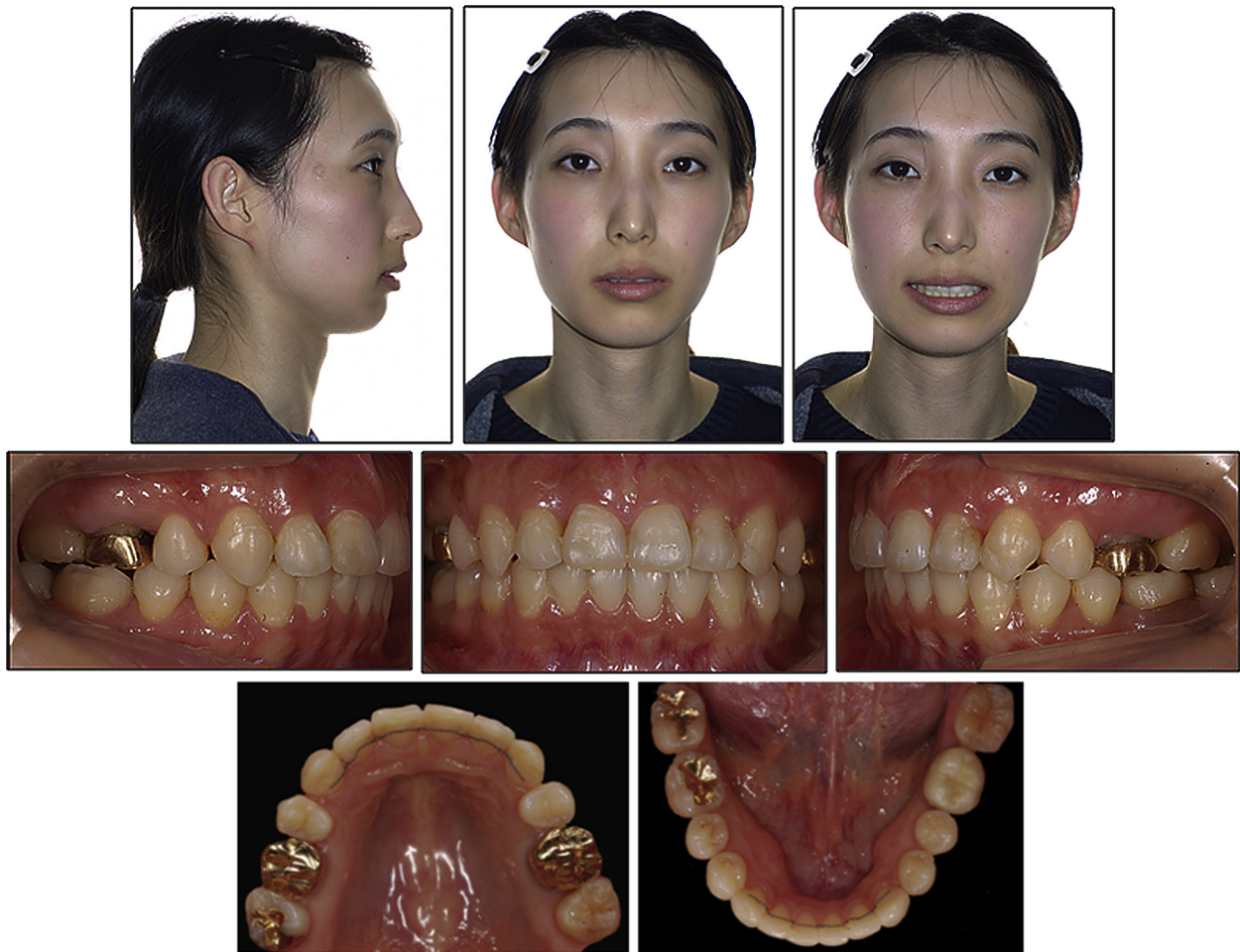

Fig 7. Posttreatment facial and intraoral photographs.

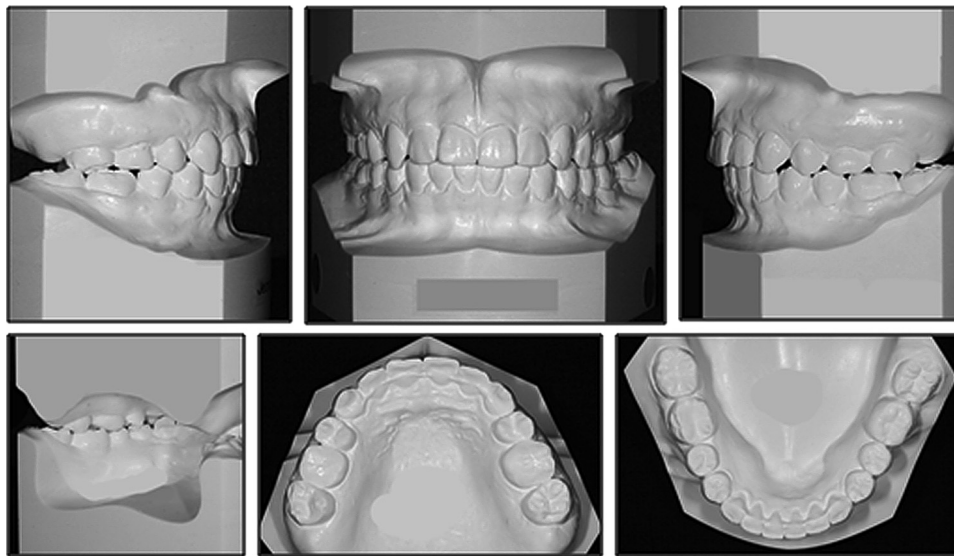especially the protrusion of her lips, was improved (Figs 7 and 10). At the 9-month retention examination, the records showed no significant relapse, and the patient had a stable occlusion (Figs 11 and 12).

## DISCUSSION

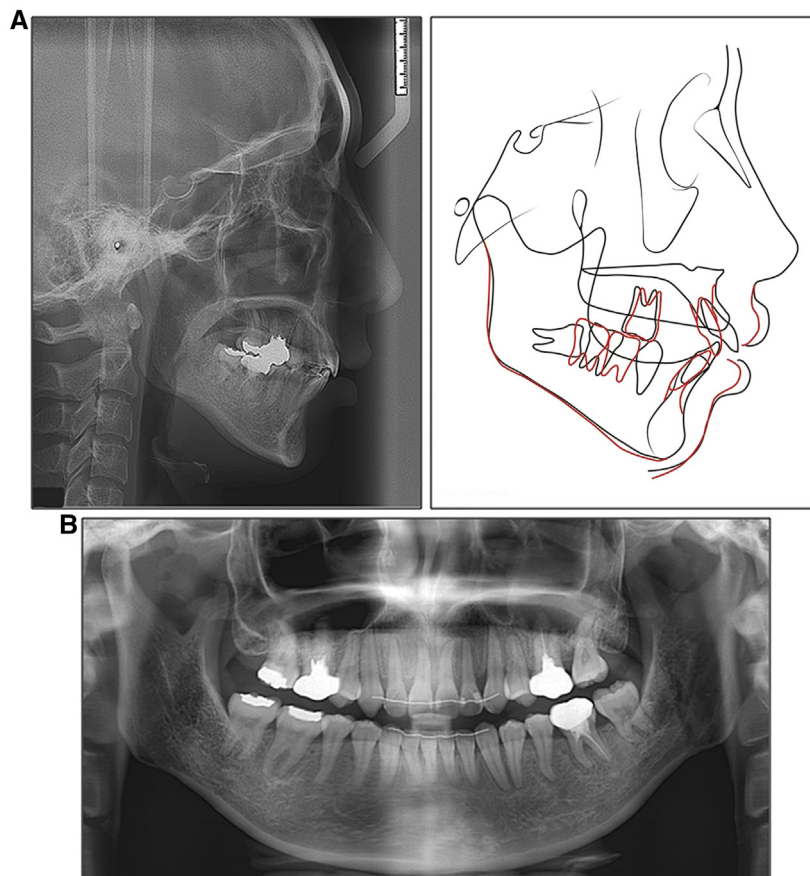
If a first molar is lost without any remedy to treat the open space, occlusal forces can cause the adjacent teeth to tip into the space. Tipped molars can create increased soft tissue pocketing that can compromise the health of the remaining distal teeth. By protracting the remaining molars, these detrimental effects are prevented. Studies have reported that posterior mandibular spaces from 8 mm<sup>13</sup> to 12 mm<sup>2</sup> have been closed by protracting posterior teeth. Follow-ups of these patients showed that once mesialized and stabilized, the posterior teeth remained protracted without reopening of the edentulous spaces or increased pocket depth.<sup>2,13</sup>

It was initially believed that protracting a molar into an edentulous space with a thin resorbed ridge would compromise the protracted tooth because of decreased osseous support.<sup>14</sup> However, previous studies have found that this may not be the case.<sup>13,15</sup> In the case presented by Nagaraj et al,<sup>13</sup> an increase of 1.5 mm in alveolar ridge width was seen, but there was no significant increase in ridge height, so protracting the molars may benefit the patient by increasing alveolar ridge width that had previously been lost in the edentulous space. For an edentulous space created by a congenitally missing tooth or an extraction at an early age, protraction of the molars should ideally be done before significant vertical bone resorption occurs.<sup>16</sup>

TSADs have simplified orthodontic treatment. For patients with missing mandibular first molars, conventional treatment has been to place either dental bridges or dental implants, but with the introduction of TSADs, orthodontists can efficiently close the gaps from missing

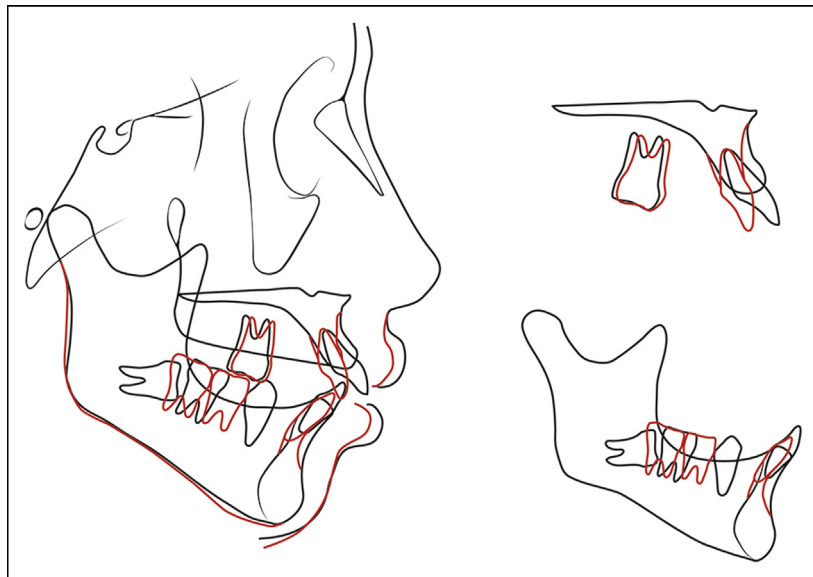


**Fig 8.** Posttreatment dental casts.

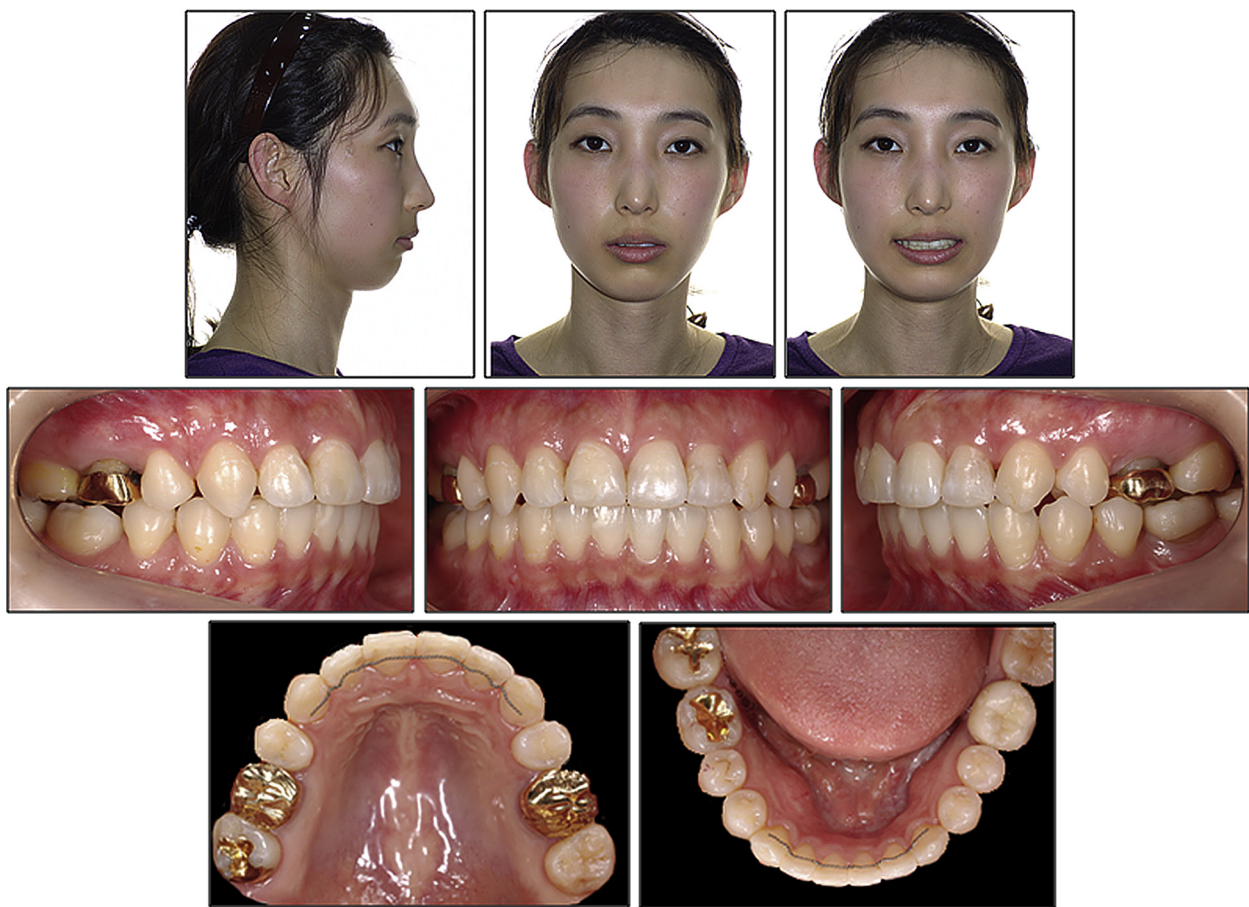

**Fig 9.** Posttreatment radiographs: **A**, lateral cephalogram; **B**, panoramic radiograph.

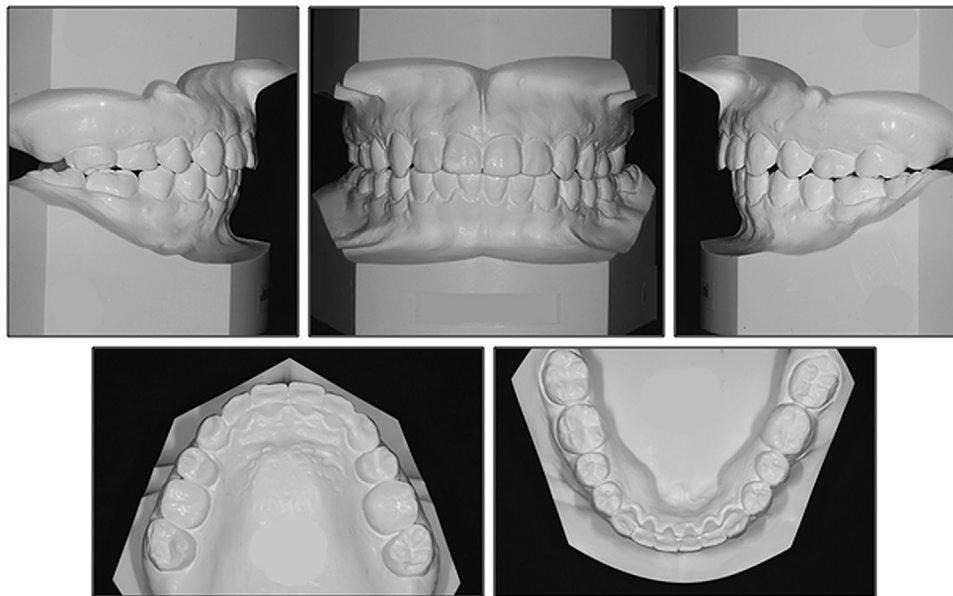



**Fig 10.** Cephalometric superimpositions. *Black*, pretreatment; *red*, posttreatment.



**Fig 11.** Nine-month posttreatment facial and intraoral photographs.



**Fig 12.** Nine-month posttreatment dental casts.

teeth rather than treat the spaces with restorations. During molar protraction, a long buccal hook, an uprighting spring, a toe-in bend in the posterior portion of the arch-wire with constriction, or a balancing lingual force can be used to prevent side-effects such as posterior tooth tipping, mesial rotation, and buccal sweep.<sup>3</sup>

The advancing technology of orthodontic miniscrews allows for better manipulation of the second and third molars to close spaces created by missing first molars.<sup>2</sup> However, because of potential distal periodontal complications in the second molars, it is important to predict how the third molar impaction will affect the periodontal health of the second molars in postorthodontic treatment. Hence, if we are substituting third molars for second molars, it is important to evaluate angulation, eruption space, root developmental stage, and periodontal status of the mandibular third molars.<sup>17</sup>

There is little possibility that posterior crossbites will self-correct, and they are extremely difficult to treat if not corrected at an early stage.<sup>5</sup> Several etiologies have been identified as the cause of a posterior crossbite: eg, sucking habits, obstruction of the upper airway, and certain swallowing patterns.<sup>18</sup> In these conditions, most patients have an arch-width discrepancy between the maxillary and mandibular arches because of insufficient maxillary arch width. In patients with deciduous or mixed dentition, expanding the maxillary arch width should be a major goal of posterior crossbite treatment.<sup>19</sup>

Previous studies have reported that even if there was no arch-length discrepancy in the posterior segments,

the mandibular second molars tend to erupt lingually, producing a buccal crossbite or a scissors-bite.<sup>7,18,20</sup> In our patient, the mandibular left second molar had lingual tilting, but the position of the tooth was not exacerbated after extraction of the carious mandibular first molar, since she reported that the extraction had taken place just a few months earlier. Yun et al<sup>7</sup> stated that the main problems in correcting a scissors-bite are buccal tipping and extrusion of the maxillary molar, lingual tipping and extrusion of the mandibular molar, lack of space for appliance placement, and molar position resistant to correction. They also mentioned that the keys to successful correction of a scissors-bite are intrusion and palatal tipping of the maxillary molar along with uprighting of the mandibular molar without loss of anchorage.<sup>7</sup>

Following are some methods presented in the literature for correction of buccal posterior crossbites in the permanent dentition: modified transpalatal arch,<sup>21</sup> cross-arch elastics,<sup>22</sup> and dragon helix appliance with miniscrews.<sup>7</sup> We also considered an indirect skeletal anchorage system to correct the scissors-bite after bonding the fixed orthodontic appliances, but the patient did not want miniscrews placed until we reached the stage of leveling her teeth.<sup>7</sup> To correct her scissors-bite, we used appliances similar to those developed by Nakamura et al<sup>23</sup>: a modified transpalatal arch with a soldered hook on the maxillary arch and a modified lingual holding arch with a soldered hook on the mandibular arch. Both served as anchorage units. An elastomeric chain was attached to the hook from a

button bonded to the buccal surface of the maxillary second molar and was run over the crown to create an intrusive force and lingual traction. The same method was used on the lingual surface of the mandibular second molar to produce an intrusive force and buccal traction (Fig 4).

## CONCLUSIONS

The advantages of molar protraction include the possibility of using the patient's natural dentition, decreased pain or trauma from third molar extractions, decreased risk of distal caries of the second molar, and reduced pericoronitis of the third molar. In our patient, complete closure of the edentulous first molar space was achieved with TSADs and the buccal crossbite was corrected with a modified transpalatal arch and a mandibular lingual holding arch.

## SUPPLEMENTARY DATA

Supplementary data related to this article can be found online at <http://dx.doi.org/10.1016/j.ajodo.2016.01.019>.

## REFERENCES

1. Tsui WK, Chua HD, Cheung LK. Bone anchor systems for orthodontic application: a systematic review. *Int J Oral Maxillofac Surg* 2012;41:1427-38.
2. Baik UB, Chun YS, Jung MH, Sugawara J. Protraction of mandibular second and third molars into missing first molar spaces for a patient with an anterior open bite and anterior spacing. *Am J Orthod Dentofacial Orthop* 2012;141:783-95.
3. Baik UB, Park JH. Molar protraction: orthodontic substitution of missing posterior teeth. North Charleston, SC: CreateSpace; 2013. p. 96-103.
4. Erdinç AE, Ugur T, Erbay E. A comparison of different treatment techniques for posterior crossbite in the mixed dentition. *Am J Orthod Dentofacial Orthop* 1999;116:287-300.
5. Valencia RM. Treatment of unilateral buccal crossbites in the primary, early mixed, and permanent dentitions: case reports. *J Clin Pediatr Dent* 2007;31:216-20.
6. Vargervik K. Morphologic evidence of muscle influence on dental arch width. *Am J Orthod* 1979;76:21-8.
7. Yun SW, Lim WH, Chong DR, Chun YS. Scissors-bite correction on second molar with a dragon helix appliance. *Am J Orthod Dentofacial Orthop* 2007;132:842-7.
8. Petren S, Bondemark L. Correction of unilateral posterior crossbite in the mixed dentition: a randomized controlled trial. *Am J Orthod Dentofacial Orthop* 2008;133:790.e7-13.
9. Wright CF. Crossbites and their management. *Angle Orthod* 1953;23:35-45.
10. Handelman C. Palatal expansion in adults: the nonsurgical approach. *Am J Orthod Dentofacial Orthop* 2011;140:462-9.
11. Park HS, Kwon DG, Sung JH. Nonextraction treatment with micro-screw implant. *Angle Orthod* 2004;74:539-49.
12. Park JH, Tai K, Takagi M, Miyajima K, Kojima Y, Joo BH. Esthetic orthodontic treatment with a double J retractor and temporary anchorage devices. *Am J Orthod Dentofacial Orthop* 2012;141:796-805.
13. Nagaraj K, Upadhyay M, Yadav S. Titanium screw anchorage for protraction of mandibular second molars into first molar extraction sites. *Am J Orthod Dentofacial Orthop* 2008;134:583-91.
14. Kessler M. Interrelationships between orthodontics and periodontics. *Am J Orthod* 1976;70:154-72.
15. Hom BM, Turley PK. Effects of space closure of mandibular first molar area in adults. *Am J Orthod* 1984;85:457-69.
16. Proffit WR, Fields HW, Sarver DM. Contemporary orthodontics. 5th Ed. Philadelphia: Mosby Elsevier; 2013. p. 277-311.
17. Baik UB, Kook YA, Bayome M, Park JU, Park JH. Vertical eruption patterns of the impacted mandibular third molars after the mesialization of second molars using miniscrews. *Angle Orthod* 2016;86:565-70.
18. Tollaro I, Defraia E, Marinelli A, Alarashi M. Tooth abrasion in unilateral posterior crossbite in the deciduous dentition. *Angle Orthod* 2002;72:426-30.
19. Toroglu MS, Uzel E, Kayalioglu M, Uzel I. Asymmetric maxillary expansion (AMEX) appliance for treatment of true unilateral posterior crossbite. *Am J Orthod Dentofacial Orthop* 2002;12:164-73.
20. Pinto AS, Buschang PH, Throckmorton GS, Chen P. Morphological and positional asymmetries of young children with functional unilateral posterior crossbite. *Am J Orthod Dentofacial Orthop* 2001;120:513-20.
21. Gerhard K, Weiland FJ. Goal-oriented positioning of maxillary second molars using the palatal intrusion technique. *Am J Orthod Dentofacial Orthop* 1996;110:466-8.
22. de Menezes LM, Ritter DE, Locks A. Combining traditional technique to correct anterior open bite and posterior crossbite. *Am J Orthod Dentofacial Orthop* 2013;143:412-20.
23. Nakamura S, Miyajima K, Nagahara K, Yokoi Y. Correction of single-tooth crossbite. *J Clin Orthod* 1995;29:257-62.